

Introduction

- Air embolism is the entry of air into vascular structures that can lead to serious morbidity and mortality¹.
- It is a condition that is often under recognized and for the most part iatrogenic secondary to various clinical procedures.
- Air can enter the vascular structures through venous or arterial system which are distinguished based on the mechanism of air entry and the final site of emboli lodging¹.
- We report a case of air embolism associated with Transcatheter Aortic Valve Replacement (TAVR) via transfemoral approach leading to a right posterior cerebral artery (PCA) infarction.

Clinical Presentation

- A 75 year old male with history of atrial fibrillation, prior cerebral infarction (without any residual deficits), hypertension, hyperlipidemia, diabetes mellitus, congestive heart failure with pacemaker, coronary artery disease with multiple stents, chronic kidney disease, abdominal aortic aneurysm status post repair and severe aortic valve stenosis was admitted to the hospital for chest pain and shortness of breath.
- He underwent TAVR around 3:30 PM. After the procedure he was initially drowsy which was attributed to the anesthesia given during the procedure.
- Stroke page was activated at 8:22 PM when his wife noted left lower facial droop. On neurology evaluation, he was found to have left sided weakness, no blink to threat on left, right gaze preference and dysarthria. NIHSS score was 10 on initial evaluation.
- Patient was not a tPA candidate as his last known normal was prior to the procedure.
- CTA did not show any large vessel occlusion amenable to intervention. However, it revealed right PCA (P2 division) air embolus.
- Repeat CTH revealed moderate volume right posterior cerebral artery distribution infarction without hemorrhagic transformation and the air embolus was not seen.
- Appropriate supportive care was provided and he was subsequently transferred to rehab service.

Neurological Examination

MS	Drowsy, but oriented to person, place not time. Able to follow simple commands. Mild dysarthria.
CN	No blink to threat on left; right gaze preference but able to cross midline; left nasolabial fold flattening.
Motor	Decreased tone on the left. Left hemiparesis (4/5). Rest 5/5.
Sensory	Intact.
Reflexes	2+ throughout. Absent Babinski.
NIHSS	10 1a - LOC1-drowsy 1b - LOC Questions 1-one 2 - Best Gaze 1-partial 3 - Visual Fields 2-complete 4 - Facial Paresis 1-minor 6 - Left Arm 1-drift 7 - Right Leg X-untestable 8 - Left Leg 2-some effort vs. gravity 12 - Dysarthria 1-mild/moderate

Treatment

- The treatment for air embolism starts with achieving hemodynamic stability.
- Further entry of air must be prevented by finding the source and taking measures to avoid further air entry.
- Patients need to be well hydrated to maintain central venous pressure of 10-15 mmHg to reduce the pressure gradient and maintain perfusion pressure.
- 100% oxygen should be provided to maintain adequate oxygen delivery to tissues and reduce the bubble size by creating diffusion gradients for oxygen to enter and nitrogen to exit the bubble.
- If available in a timely manner, this process can be done more effectively using a hyperbaric oxygen chamber^{1,4}.

Final Diagnosis - Right Posterior Artery Infarct from Air Embolism

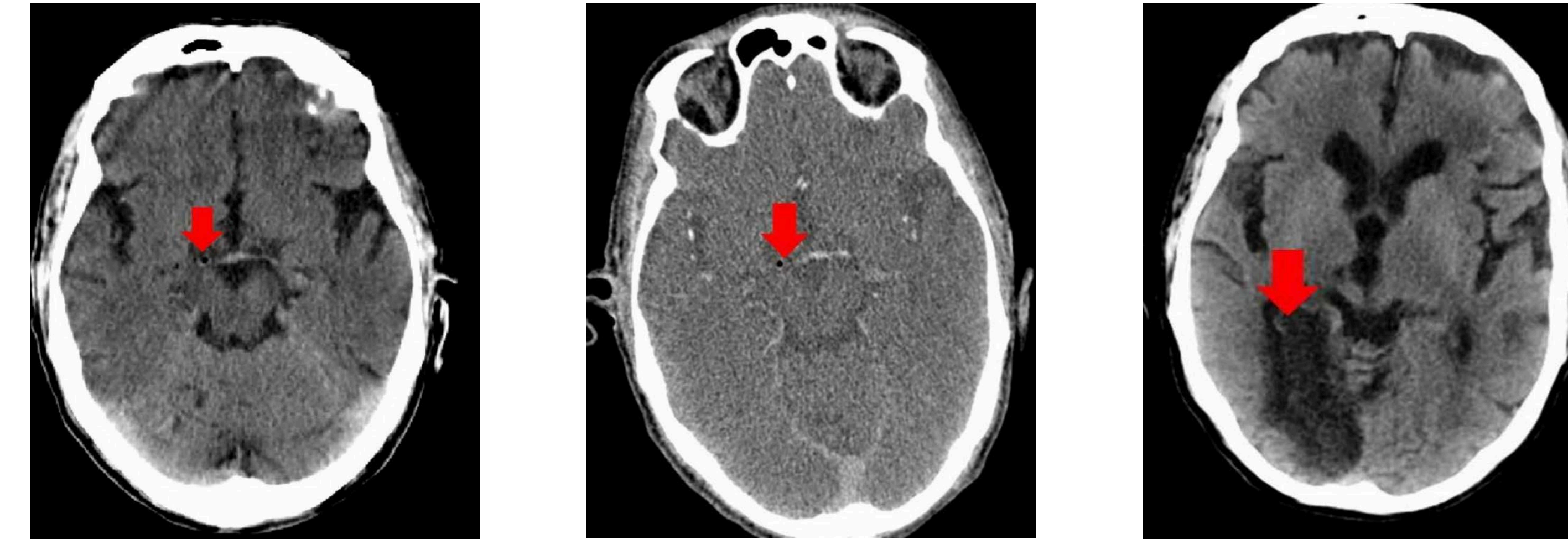


Figure 1 & 2: Initial imaging revealed no thrombus but an air embolus in the right P2 division of the posterior cerebral artery which was more clearly visible on CT angiography.

Figure 3: Repeat CTH revealed moderate volume right posterior cerebral artery distribution infarction without hemorrhagic transformation with resolution of the air embolus previously seen.

Discussion

- TAVR is a minimally invasive technique that eliminates the need for sternotomy, hence its popular use in high risk aortic stenosis patients.
- In recent years, TAVR is being utilized more routinely than surgical aortic valve replacement given its comparable cerebrovascular complications².
- Although various surgeries and procedures have been associated with air embolism, to our knowledge a case of air embolism leading to a stroke after TAVR has not been reported.
- Arterial air embolism is caused by entry of air into the pulmonary veins or directly into the arteries of the systemic circulation¹.
- Air that is introduced peripherally can travel retrograde to central arteries causing myocardial infarction and stroke.
- Although there have been reports of fatal cerebral arterial embolism secondary to large venous emboli without any demonstration of intracardiac defects or shunt mechanisms³, in our patient's case it is likely that an arterial air embolus emerged from the femoral artery puncture site in the groin for the TAVR and travelled retrograde to the cerebral circulation causing the infarct.

Conclusion

Air embolism is a condition that is often under recognized and for the most part iatrogenic secondary to various clinical procedures. Here we report a case of air embolism associated with Transcatheter Aortic Valve Replacement (TAVR) via transfemoral approach leading to a right posterior cerebral artery (PCA) infarction. This case emphasizes the fact that air emboli prevention should be an important part of any surgical procedure requiring insertion of central lines.

References

1. Muth CM, Shank ES. Gas Embolism. N Engl J Med. 2000; 342(7):476-82.
2. Mohananey D, Sengodan P, Banerjee K, et al. Comparative analysis of cerebrovascular events in transcatheter and surgical aortic valve replacement: a systematic review and meta-analysis of randomised trials. EuroIntervention. 2018;14(1):69-77.
3. Tommasino C, Rizzardi R, Beretta L, et al. Cerebral ischemia after venous air embolism in the absence of intracardiac defects. J Neurosurg Anesthesiol. 1996;8(1): 30-4.
4. Palmon SC, Moore LE, Lundberg J, Toung T. Venous air embolism: a review. J Clin Anesth. 1997;9(3):251-7.

