

SILENT MRI WHITE MATTER LESIONS IN PATIENTS WITH CIS SUGGESTIVE OF MULTIPLE SCLEROSIS



Suarez-Zambrano GA, Ramirez J , Avila M, Brandt D, Escobar BH, Hutton GJ, Rivera VM

Introduction: Clinically Isolated Syndrome (CIS) is a neurological event due to a single central nervous system (CNS) lesion usually lasting longer than 24 hours and resolving within weeks. Typically, 30-70% of patients with CIS will develop definite MS. The most commonly affected areas are the optic nerves, cerebellum, brainstem (OCB) and spinal cord (SC). Studies have demonstrated a direct relationship with the number and volume of lesions detected in the MRIs and the risk for developing MS(1-3). We hypothesized that, besides obtaining images of the symptomatic area of the CNS, non affected areas should be studied as well. Such a topic has been evaluated previously (4). Identifying asymptomatic lesions will help us in the difficult decision of stratifying the risk for development of definite MS and in the consideration of treatment(5).

Objectives: To assess the frequency of asymptomatic cord lesions in patients with a OCB CIS and the frequency of asymptomatic OCB lesions in patients with SC CIS respectively.

Materials and Methods: Retrospective study in progress. We identified subjects that presented to an MS clinic in Houston, Texas with a diagnosis of CIS.

Results: We have identified 13 subjects out of the 50 individuals we are expecting to enroll, 84% female and 16% male. 46% had an initial episode of optic neuritis and 31% myelitis (figure 1). Of the patients with an initial OCB event (69%), 6/9 had clear abnormalities on the brain MRI suggestive of demyelination. We found abnormalities in the cord MRIs in 4/9 (figure 2). Of the patients with an initial SC event, all 4 had abnormalities in the cervical MRI and 2 had an abnormal brain MRI.

Figure 1. Initial event

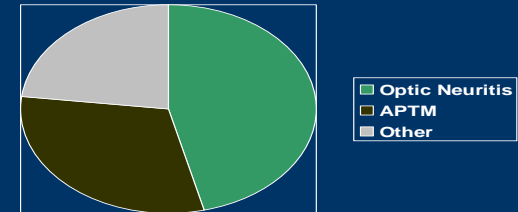
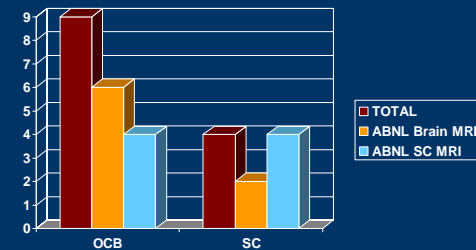


Figure 2. MRI findings according to the initial CIS subtype



Conclusions: A trend to identify asymptomatic white matter lesions in other areas of the CNS is noted in almost 50% of the patients with CIS. This will help with the decision about which patients will be best candidates for early therapy therefore delaying definite MS.

References:

1. Brex P, et al. N Eng Med 2002;346:158.
2. Tintore M, et al. Neurology 2008;70:1079.
3. Fisniku LK, et al. Brain 2008;131(3):808.
4. O'Riordan et al. JNNP 1998;64:353.
5. Frohman E, et al. Neurology 2003;61:602.

