

## Uncinate fasciculus integrity and impaired problem solving and memory in complex partial seizures

Mario F. Dulay, PhD.<sup>1</sup>, Christof Karmonik, Ph.D.<sup>1</sup>, Amit Verma, M.D.<sup>1</sup>, Kimberly P. Raghubar, M.A.<sup>1</sup>, Adriana M. Strutt, Ph.D.<sup>2</sup>, Michele K. York, Ph.D.<sup>2</sup>, Robert G. Grossman, M.D.<sup>1</sup>  
The Methodist Hospital Neurological Institute<sup>1</sup> and the Department of Neurology, Baylor College of Medicine<sup>2</sup>

### BACKGROUND

- ✓ Executive functions refer to complex behavioral processes associated with frontal lobe functioning that involve planning actions, initiating actions, adapting to and solving problems, using feedback to choose future responses, inhibiting undesirable or incorrect responses, and using strategies to remember.
- ✓ A subset of individuals with complex partial seizures of the temporal lobe have unexpected executive function impairments, as well as expected memory impairments.<sup>1</sup>
- ✓ The uncinate fasciculus (UF) has been found to be associated with attention, set shifting, emotion regulation, intelligence and memory difficulties in various populations (e.g., healthy older adults, mild cognitive impairment, schizophrenia, depression), as well as memory impairment in patient with epilepsy.<sup>2,3,4,5,6</sup>

### OBJECTIVE

- ✓ The purpose of this study was to relate the structural integrity of the uncinate fasciculus, a corticocortical fiber tract connecting the frontal and temporal lobes, to functional measures of memory and problem solving in individuals with complex partial seizures.

### PARTICIPANTS

Ten patients (5 women) diagnosed with video-EEG confirmed intractable TLE (4 left, 6 right) underwent DTI and neuropsychological assessment. Table 1 shows the demographic and disease-related data for the sample.

Table 1. Sample characteristics

|                           | Left-TLE |      | Right-TLE |      |
|---------------------------|----------|------|-----------|------|
|                           | M        | SD   | M         | SD   |
| Chronological Age (yr.)   | 38.3     | 14.9 | 28.0      | 8.8  |
| Education (yr.)           | 12.3     | 1.6  | 12.7      | 1.2  |
| Seizure Frequency (mo.)   | 6.7      | 4.2  | 21.3      | 15.0 |
| Age at Onset (yr.)        | 22.7     | 4.2  | 10.7      | 8.4  |
| Duration of Illness (yr.) | 14.0     | 15.8 | 17.0      | 9.5  |

### DTI procedures

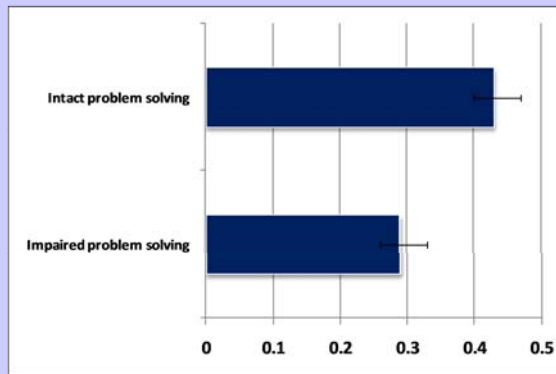
Mean FA was computed for the left and right uncinate fasciculus using an algorithm for the voxel-based automated registration of DTI images using the ICBM 81 white matter atlas implemented within AFNI software. Whole brain DTI images were retrospectively analyzed from a Siemens scanner (acquisition matrix 128x96, interpolated in-plane resolution 1.88 mm x 1.88 mm, echo time 79 msec, number of averages 8, slice thickness ranged from 1 - 3 mm, with at least 12 directions).

### Neurocognitive Procedures

Neuropsychological tasks included measures of set shifting and adaptation (Wisconsin Card Sorting Test), problem solving (Matrix Reasoning), mental flexibility (Trail Making Test), and strategic visual and verbal learning (Verbal and Nonverbal Selective Reminding Tests, Rey-Osterrieth Complex Figures Test).

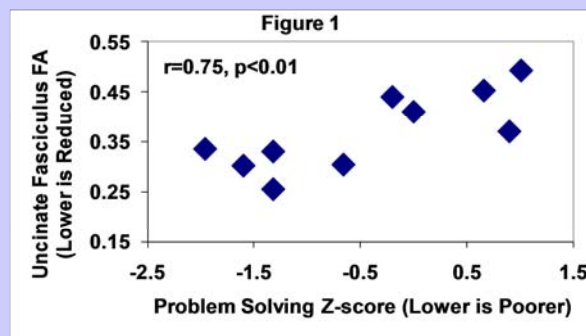
### RESULTS (Table 2)

One-way ANOVA indicated that patients with problem solving impairment (z-score -1.32 below normative data) had significantly lower mean uncinate fasciculus FA values ( $F[1,9]=6.2, p < 0.05$ ; Table below). Specifically, the four patients with impaired problem solving ability had lower mean uncinate fasciculus FA values compared to patients with relatively intact problem solving ability.



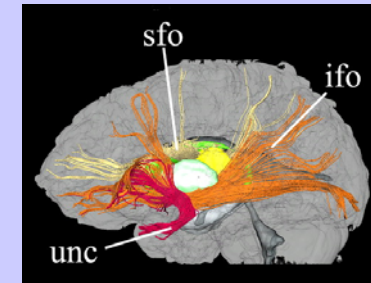
### RESULTS (Figure 1)

Controlling for age, lower left uncinate fasciculus FA values were significantly correlated with problem solving ( $r = 0.75$ ; see Figure 1), mental flexibility ( $r = -0.68$ ), verbal learning ( $r = 0.81$ ), and visual constructional learning ( $r = 0.72$ ; see Figure 2; all  $p$  values  $< 0.05$ ). Spatial learning impairment was the only ability associated with lower right uncinate fasciculus FA values ( $r = 0.77, p < 0.05$ ).



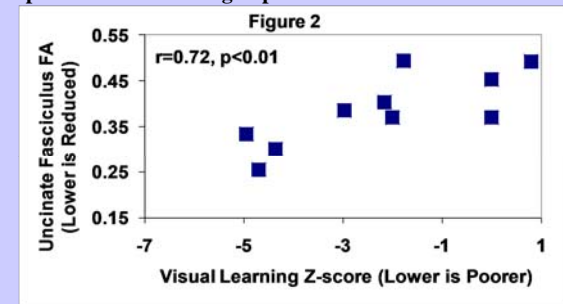
### Uncinate Fasciculus

The uncinate fasciculus ('unc' portrayed in red in the Figure below from Wakana et al., 2004)<sup>7</sup> is a white matter tract that connects parts of the temporal lobe (e.g., amygdala and hippocampus) with the frontal lobe (e.g., orbitofrontal cortex).



### RESULTS (Figure 2)

Lower left uncinate fasciculus FA was significantly associated with poorer visual learning in patients with CPS.



### CONCLUSIONS

✓ Results are consistent with previous studies that have found associations between unilateral UF white matter tract integrity and cognition. Disruption of the UF may partly explain the executive and strategic memory impairments found in individuals with CPS. Studies with larger sample sizes are needed to replicate our structure-function correlations.

### REFERENCES

- Dulay MF, York MK, Soety EM, Hamilton WJ, Mizrahi EM, Goldsmith IL, Verma A, Grossman RG, Yoshor D, Armstrong DD, Levin HS. Memory, emotional and vocational impairments before and after anterior temporal lobectomy for complex partial seizures. *Epilepsia* 2006;47:1922-30.
- Zahr NM, Rohlfing T, Pfefferbaum A, Sullivan EV. Problem solving, working memory, and motor correlates of association and commissural fiber bundles in normal aging: A quantitative fiber tracking study. *NeuroImage*. 2009;44:1059-1062.
- Perry ME, McDonald CR, Hagler DJ Jr, Gharapetian L, Kuperman JM, Koyama AK, Dale AM, McEvoy LK. White matter tracts associated with set-shifting in healthy aging. *Neuropsychologia* 2009;47:2835-42.
- McDonald CR, Ahmadi ME, Hagler DJ, Tecoma ES, Iragui VJ, Gharapetian L, Dale AM, Halgren E. Diffusion tensor imaging correlates of memory and language impairments in temporal lobe epilepsy. *Neurology* 2008;71:1869-76.
- Diehl B, Busch RM, Duncan JS, Piao Z, Tkach J, Lüders HO. Abnormalities in diffusion tensor imaging of the uncinate fasciculus relate to reduced memory in temporal lobe epilepsy. *Epilepsia*. 2008 Aug;49(8):1409-18.
- Nestor PG, Kubicki M, Niznikiewicz M, Gurrera RJ, McCarley RW, Shenton ME. Neuropsychological disturbances in schizophrenia: a diffusion tensor imaging study. *Neuropsychology* 2008;22:246-54.
- Wakana S, Jiang H, Nagae-Poetscher LM, van Zijl PC, Mori S. Fiber tract-based atlas of human white matter anatomy. *Radiology* 2004;230:77-87.